

Overlooked and Delayed Diagnosis of Tibial Plateau Fracture

Petar Avramovski^{1*}, Vesna H Siklovska², Aleksandar Obednikovski³, Maja Avramovska⁴, Simeon Siljanovski², Aleksandar Dimovski² and Emilija Sikole⁵

¹Professor, Department of Internal Medicine, Clinical Hospital D-r Trifun Panovski, North Macedonia

²Radiologist, Department of Radiology, Clinical Hospital D-r Trifun Panovski, North Macedonia

³Ortopedic, Traumatologist, Department of Orthopaedics and Traumatology, Clinical Hospital D-r Trifun Panovski, North Macedonia

⁴Gynecologist, Department of Obstetrics and Gynecology, Clinical Hospital D-r Trifun Panovski, North Macedonia

⁵Institute of Preclinical and Clinical Pharmacology with Toxicology, Ss. Cyril and Methodius University of Skopje, Skopje, North Macedonia

***Corresponding Author:** Petar Avramovski, Professor, Department of Internal Medicine, Clinical Hospital D-r Trifun Panovski, North Macedonia.

Received: January 07, 2020; **Published:** February 18, 2020

Abstract

Introduction: Tibial plateau fractures (TPFs) are one of the most common radiological pathologies to be overlooked by doctors and represent a wide spectrum of severity which ranges from simple injuries to complex fracture patterns. The treatment of the TPFs varies depending on type, mechanism of injury, and patient characteristics.

Case Presentation: We report the case of one male 57-aged patient who sustained TPF fracture with depression of lateral tibial condyle and bleeding into joint spaces. The fracture was overlooked in image acquired by X-ray on standard anteroposterior view of the right proximal tibia, at the first radiologic examination. Diagnose of TPF was delayed until magnetic resonance imaging (MRI) was performed. Anteroposterior and lateral X-ray reassessment of the knee proved that TPF was overlooked.

Conclusion: We found two reasons for overlooking TPF in the emergency room, first, that TPF was not identified by standard X-ray imaging because the lateral X-ray and MRI were not acquired. The presentation of this case report of overlooked and delayed diagnosis of TPF was intended to put attention to a common mistake made by orthopedists who did not indicate proper imaging technique and by radiologists who did not detect the TPFs.

Keywords: Tibial Fracture; Overlooked Diagnosis; X-Ray Imaging; Magnetic Resonance Imaging

Abbreviations

TPFs: Tibial Plateau Fractures; MRI: Magnetic Resonance Imaging; PKRs: Pittsburgh Knee Rules

Introduction

Tibial plateau fractures (TPFs) comprise 1% of fractures in all age groups and 8% in the elderly population [1]. TPFs are one of the most common radiological pathologies to be overlooked by doctors [2], because it is difficult to be recognized on standard radiographs since the uninjured joint surface is often projected on top of the fractured part of the tibiae plateau in the anterior-posterior, and side views [3]. TPFs frequently have important soft tissue injuries that are difficult to diagnose on physical examination. Magnetic resonance imaging (MRI) scanning should be considered for TPFs due to high-energy mechanism, allowing identification and treatment of associated soft tissue injuries with injury to the ligaments and menisci of the knee [4]. When a skeletal x-ray imaging study is misinterpreted or delayed, patient care may be neglected. Severe complications may be seen with these injuries, especially after higher grade fractures [5]. TPFs present a challenge to treating trauma and orthopaedic surgeons. Appropriate adequate early treatment implies anatomic joint reduction, alignment of the extremity and early motion to prevent stiffness [6]. These injuries are complicated by patient's comorbidities (osteoporosis, rheumatoid arthritis, diabetes, obesity...), preexisting osteoarthritis, and lower levels of preinjury functional and ambulatory status [7].

Fractures of the lateral plateau are much more common than the medial plateau, which requires a large amount of force. TPFs usually occur due to high-energy trauma, characteristically produced by varus or valgus forces coupled with axial loading [8]. A special type of TPF is a bumper fracture: a fracture of the lateral tibial plateau caused by bumper of a car coming into contact with the outer side of the knee when a person is standing. Specifically, it is caused by a forced valgus applied to the knee.

The small number of studies (only two) addressing overlooked TPFs [7], whereas the other describes eight overlooked osteoporotic fractures in elderly patients [9,10] has motivated us to present a case report of overlooked and delayed diagnosis of TPF.

We present the rare case of a 57-year old male with diabetes mellitus tip 2 on peroral antidiabetic therapy and angiotensin-converting enzyme inhibitors for hypertension.

Case Presentation

A 57-year old man presented to the emergency orthopaedics room after a fall from a height, which lost the right knee movement with pain, swelling, inability to bear weight and knee effusion. On orthopaedics examination on 20th November 2019, we found a swollen, tender joint and restricted motion of the right knee without any neurovascular deficit or compartment syndrome signs. The limb was splinted by plaster back splint and subjected to x-ray imaging.

The radiologist did not notice the fracture line and did not suspect for fracture. The fracture was overlooked.

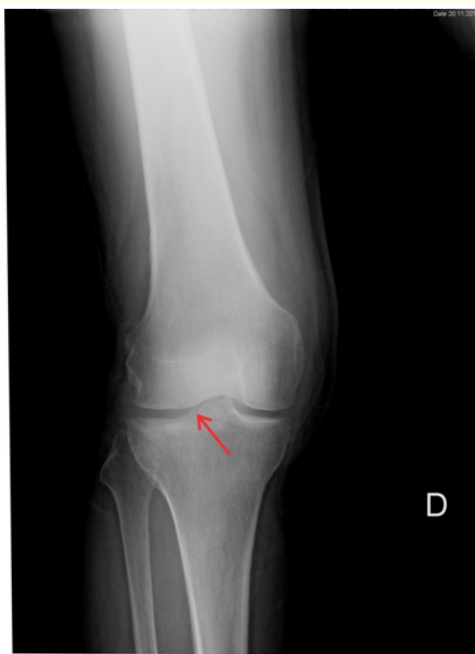


Figure 1: X-ray imaging of a lateral tibial plateau fracture (overlooked fracture).

In figure 1, acquired by X-ray, we show an anteroposterior view of the right proximal tibia with an unrecognizable initial injury (imaged on 20.11.2019). The orthopedist and radiologist told the patient that there was no fracture. He was sent to rest for home treatment

with symptomatic therapy, cold compresses analgesics and non-steroidal antirheumatics. Due to the further deterioration of the general condition with knee swelling, the patient called for a repeat orthopedic examination on 6th December 2019 and he was directed to MRI.

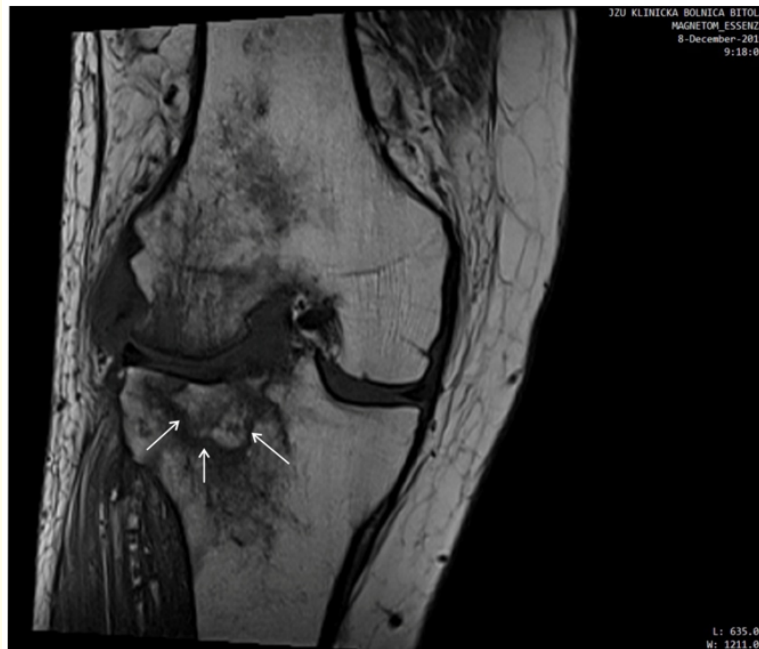

Figure 2: MRI coronal plane scan of the tibia 19 days after the time of the initial injury.

MRI was acquired at 8th December 2019. Figure 2 show MRI image of the tibial plateau of the proximal tibia in the coronal plane. The image was acquired by standard pulse sequences and standard planes. We follow the plateau fracture accompanied by depression of lateral tibial condyle and intraarticular fluid with MRI characteristics of hemarthrosis (bleeding into joint spaces). The orthopedist after the results of MRI evacuated a bloody content from the swollen knee.

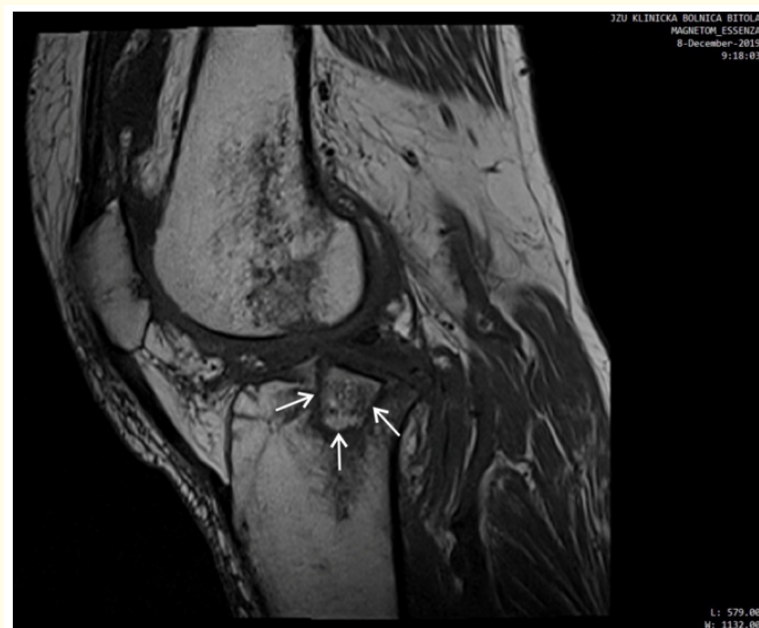

Figure 3: MRI sagittal plane scan of the tibia 19 days after the time of the initial injury.

After the patient was diagnosed with MRI, his knee joint was reimaged by X-rays. This time the fracture line of the lateral portion of the tibial plateau was detected (Figure 4).

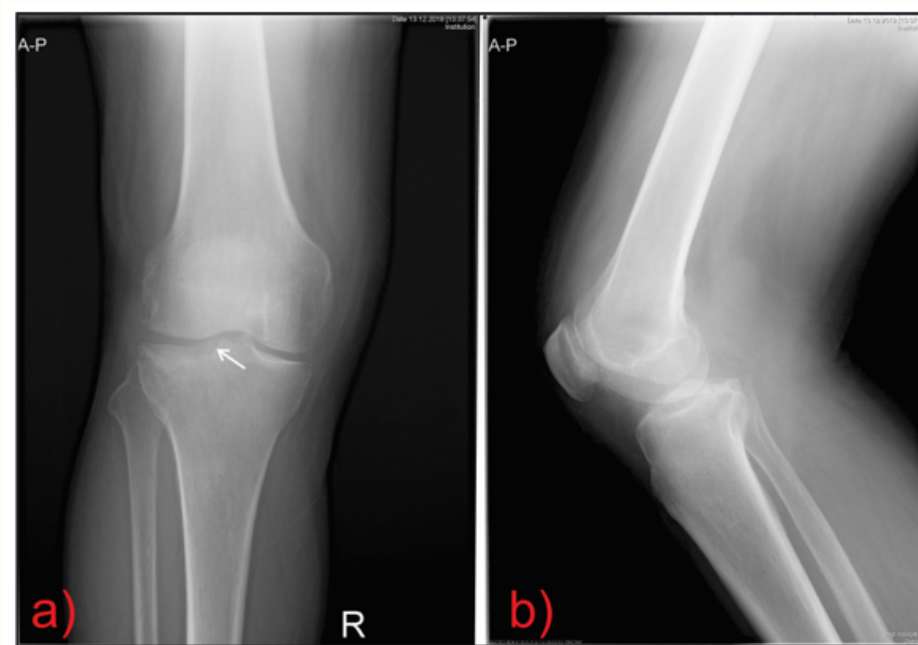


Figure 4: (a) Anteroposterior view of the right proximal tibia showing the initial injury (look at the arrow), (b) lateral view of the right proximal tibia (imaged on 13.12.2019). Note the degree of articular depression better appreciated on MRI scan.

The purpose of this X-ray re-imaging was to determine whether the fracture existed at the first radiographic scan or it was caused by an additional load on the injured leg. It was proved that the fracture was not seen at the first examination, despite being present.

The patient walked unassisted, he was pain free and, bearing full weight, with a reasonably good functional range of motion. The local examination did not reveal any signs of ligamentous laxity.

Discussion

In 84% of the cases, where an X-ray image was obtained at first medical contact, the fracture was visible or suspected at retrospective evaluation of the X-rays. TPFs scan can be hard to recognize in anterior-posterior as well as lateral projections [9,10]. Because of the anatomy of the tibial plateau, which causes a distortion in radiography, underestimating anterior surface depression and overestimating posterior surface depression is possible [11]. Sometimes, in addition, we need to make oblique projections when TPFs are suspected but not confirmed by standard AP and lateral X-rays. In that way, adding an oblique knee views, we increase the diagnostic sensitivity from 79 to 85% [12].

The Pittsburgh Knee Rules (PKRs) were developed to improve accuracy in the use of X-ray imaging in cases of acute knee injuries. PKRs have sensitivity close to 100% [13] and Cohen's kappa (κ) inter-observer agreement of 0.71 [13]. MRI-scan and CT-scan should be considered in patient cases with a clinical suspicion of a TPF and where X-ray images are normal even though CT-scans are fast and provide

a detailed view of the fracture pattern and articular surface [3]. MRI-scans are better suited for accurately displaying occult fractures and for visualizing soft tissue injuries during TPFs [14].

After the overlooked diagnosis of TPFs in first knee X-rays, because of presence and exacerbation of the clinical symptoms, we made MRI as more sensitive diagnostic imaging. After the TPF was discovered with MRI, we exposure the patients to X-ray, once again, to find the fracture line what we missed in the first AP X-ray projection. Between these imaging procedures, the patient was immobilized with a fixed knee brace and disabled from bearing weight, to prevent a potential fracture from displacement, until a final diagnosis has been proven by MRI.

Conclusion

We found the main reason for overlooking TPFs in the emergency room setting of Clinical Hospital D-r Trifun Panovski: MRI was not taken immediately, because decision rules for indication of knee MRI had not been followed in the emergency room setting.

The presentation of this case report of overlooked and delayed diagnosis of FTP was intended to put attention to a common mistake made by orthopedists who did not indicate proper imaging technique and by radiologists who did not detect the TPFs.

Acknowledgements

I would like to express their gratitude to Dipl. ing. Biljana Hristovska (informatical manager director) and Mr. Sci. D-r Zaklina Servini (head manager director) for providing me with a powerful personal computer for conducting images processing for this case report, also for the software support and DICOM viewer, thank to my friend Marjan Strkoski.

Bibliography

1. Elsoe R., *et al.* "Population-based epidemiology of Tibial plateau fractures". *Orthopedics* 38.9 (2015): 780-786.
2. Sprivulis P., *et al.* "Same-day X-ray reporting is not needed in well-supervised emergency departments". *Emergency Medicine* 13.2 (2001): 194-197.
3. Dennan S. "Difficulties in the radiological diagnosis and evaluation of tibial plateau fractures". *Radiography* 10 (2004): 151-158.
4. Stannard JP, *et al.* "Soft tissue injury of the knee after tibial plateau fractures". *Journal of Knee Surgery* 23.4 (2010): 187-192.
5. Keating JF, *et al.* "Bifocal fractures of the tibia and fibula. Incidence, classification and treatment". *Journal of Bone and Joint Surgery-British Volume* 76 (1994): 395-400.
6. Podolnik JD and Dermksian JV. "Case report of a tibial plateau fracture extending through the tibial diaphysis after low energy injury in patients with rheumatoid arthritis". *Annals of Orthopedics and Rheumatology* 3.4 (2015): 1057.
7. Biyani A., *et al.* "The results of surgical management of displaced tibial plateau fractures in the elderly". *Injury* 26.5 (1995): 291-297.
8. Langford JR., *et al.* "Tibial plateau fractures". In: Scott WN, editor, ed. *Insall and Scott Surgery of the Knee*. 5th edition Philadelphia, PA: Elsevier Churchill Livingstone (2010): 773-785.
9. Maheshwari J., *et al.* "Anterior tibial plateau fracture: an often missed injury". *Indian Journal of Orthopaedics* 48.5 (2014): 507-510.
10. Prasad N., *et al.* "Insufficiency fracture of the tibial plateau: an often missed diagnosis". *Acta Orthopaedica Belgica* 72.5 (2006): 587-591.

11. Newberg AH and Greenstein R. "Radiographic evaluation of tibial plateau fractures". *Radiology* 126.2 (1978): 319-323.
12. Gray SD, *et al.* "Acute knee trauma: how many plain film views are necessary for the initial examination?" *Skeletal Radiology* 26.5 (1997): 298-302.
13. Cheung TC, *et al.* "Diagnostic accuracy and reproducibility of the Ottawa knee rule vs the Pittsburgh decision rule". *American Journal of Emergency Medicine* 31.4 (2013): 641-645.
14. Xu Y, *et al.* "MDCT and MRI for the diagnosis of complex fractures of the tibial plateau: a case control study". *Experimental and Therapeutic Medicine* 7.1 (2014): 199-203.

Volume 7 Issue 3 March 2020

©All rights reserved by Petar Avramovski, *et al.*